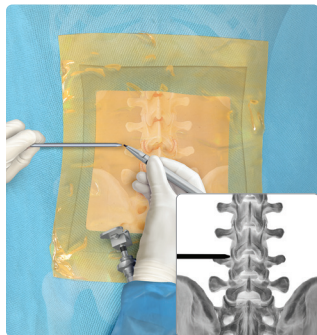


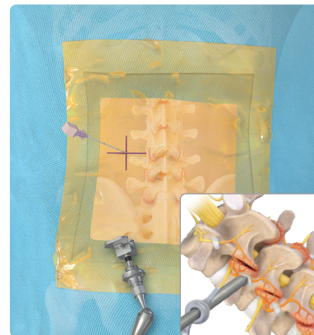Medial Branch Nerve Transection (MBT)

Quick Reference Guide

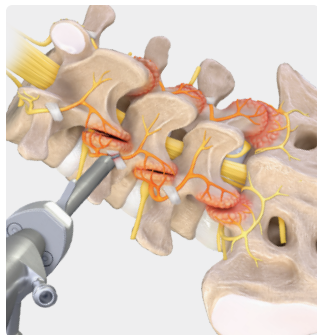
View full surgical
technique



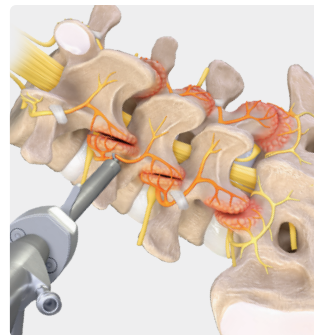
- › Use a switching stick to locate the entry point just lateral to the junction of the facet and transverse process. Mark this location.



- › Insert a spinal needle at the marked location and dock at the junction of the facet and transverse process.
- › Make an incision through the skin and fascia with a #11 blade. Remove the inner stylet from the spinal needle and insert the guidewire. Remove the spinal needle, keeping the guidewire in place.
- › Insert the switching stick over the guidewire to confirm the bony landmark.
- › Insert the cannula with the bevel opening facing medial.



- › Confirm your position by palpating the cranial and caudal aspect of the transverse process while palpating the lateral wall of the facet medially.
- › Clear soft tissue and the mamillo-accessory ligament (MAL) with the FlexTip RF probe and endoscopic instrumentation until the medial branch nerve is clearly identified.



- › Transect the medial branch nerve with an endoscopic scissor punch.
- › Use the FlexTip RF probe to ablate the ends of the nerve and fully denude the lateral facet wall from the accessory process to the mamillary process.